

Ibrutinib-Related Stellar Hematomas of the Palms

Pablo López Sanz¹, Cristina Grau Salvat¹, Inmaculada Gil Faure¹,
Joan Àngel Baldó¹, Antoni Azón Masoliver¹

¹ Department of Dermatology, Hospital Universitari Sant Joan de Reus, Tarragona, Spain

Citation: López Sanz P, Grau Salvat C, Gil Faure I, Baldó JÀ, Azón Masoliver A. Ibrutinib-related stellar hematomas of the palms. *Dermatol Pract Concept*. 2026;16(2):6118. DOI: <https://doi.org/10.5826/dpc.1602a6118>

Accepted: June 26, 2025; **Published:** April 2026

Copyright: ©2026 López Sanz et al. This is an open-access article distributed under the terms of the Creative Commons Attribution-NonCommercial License (BY-NC-4.0), <https://creativecommons.org/licenses/by-nc/4.0/>, which permits unrestricted noncommercial use, distribution, and reproduction in any medium, provided the original authors and source are credited.

Funding: None.

Competing Interests: None.

Authorship: All authors have contributed significantly to this publication.

Corresponding Author: Pablo López Sanz, MD, Department of Dermatology, Hospital Universitari Sant Joan de Reus. Avinguda del Dr. Josep Laporte N2, 43204, Reus, Tarragona, Spain. E-mail: lopezsanzpablo@gmail.com

Case Presentation

A 67-year-old woman with chronic lymphocytic leukemia treated with ibrutinib for 3 years developed multiple asymptomatic reddish-brown punctate macules on the palms with a predilection for the thenar eminence since the start of treatment (Figure 1 A and B). No systemic symptoms were present. Dermoscopy revealed red and brown globules, consistent with subcorneal hematomas (Figure 1C.). A diagnosis of ibrutinib-related stellar hematomas of the palms was continued, with lesions persisting over time.

Teaching Point

Ibrutinib-related stellar hematomas of the palms and soles is an under-recognized dermatologic manifestation associated

with Bruton's tyrosine kinase inhibitors (BTKi) such as ibrutinib with only 2 cases described in the literature [1]. Since petechiae and hematomas are common cutaneous adverse events with BTKi due to platelet signaling and glycoprotein VI inhibition impairing von Willebrand factor adhesion [2], these lesions are hypothesized to share a vascular mechanism triggered by repeated microtrauma [1]. As next-generation BTKi such as acalabrutinib and zanubrutinib also affect platelet aggregation and can cause ecchymoses and bruising, it is reasonable to speculate that palmoplantar stellar hematomas may also occur with these more selective therapies. Although discontinuing treatment might lead to lesion resolution, it is generally not recommended due to their mild and asymptomatic nature. Recognizing this rare presentation is crucial to avoid misdiagnosis and unnecessary diagnostic procedures.

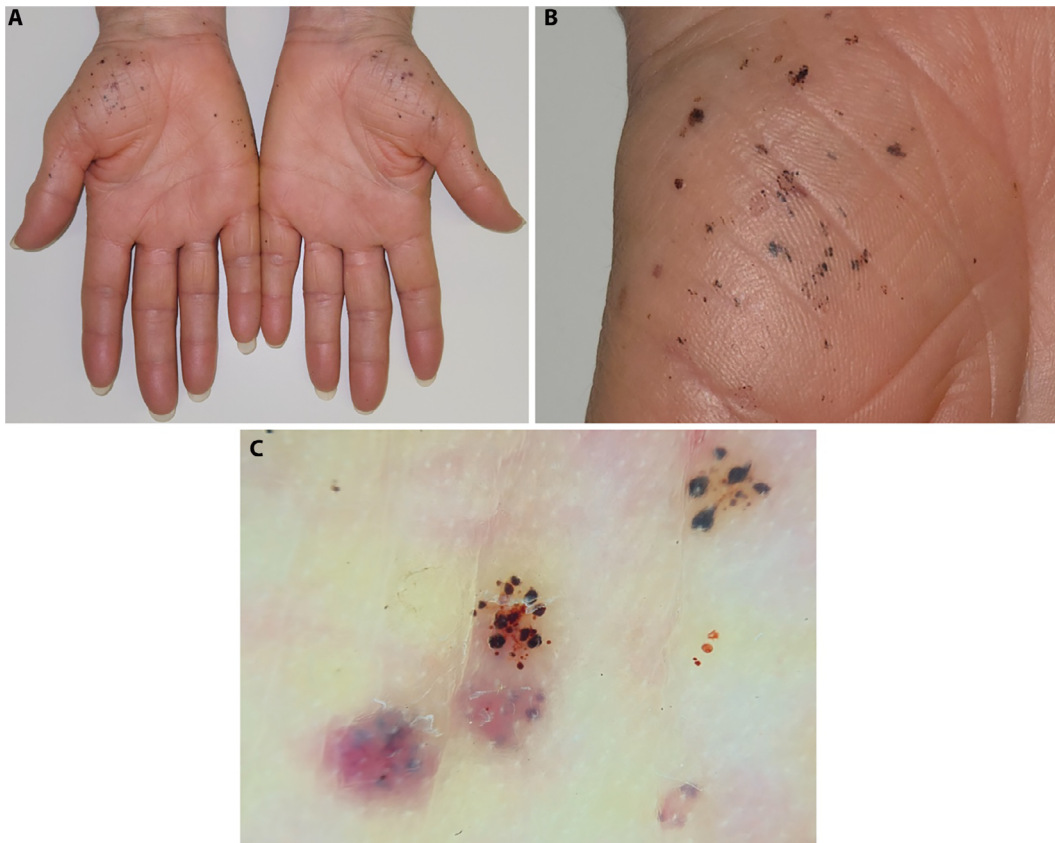


Figure 1. Multiple asymptomatic reddish-brown punctate macules on the palms with a predilection for the thenar eminence before the start of treatment (A and B). C: After dermoscopy, red and brown globules, consistent with subcorneal hematomas.

References

1. Oillarburu N, Ysebaert L, Protin C, Ortiz-Brugues A, Baali S, Parriel E, et al. Ibrutinib-related stellar hematomas of the palms and soles. *Am J Hematol.* 2025;100(5):894-896. DOI:10.1002/ajh.27514
2. Levade M, David E, Garcia C, Laurent PA, Cadot S, Michallet AS, et al. Ibrutinib treatment affects collagen and von Willebrand factor-dependent platelet functions. *Blood.* 2014;124(26):3991-3995. DOI:10.1182/blood-2014-06-583294