

eMethods

Search Strategy

First step search criteria:

1. “adenoma, pleomorphic”[MeSH Terms] AND (“cutaneous” [All Fields] OR “cutaneously”[All Fields] OR “cutaneous” [All Fields])
2. “adenoma, pleomorphic”[MeSH Terms] AND (“skin neoplasms”[MeSH Terms] OR (“skin”[All Fields] AND “neoplasms”[All Fields]) OR “skin neoplasms” [All Fields] OR (“skin”[All Fields] AND “neoplasm” [All Fields]) OR “skin neoplasm”[All Fields])

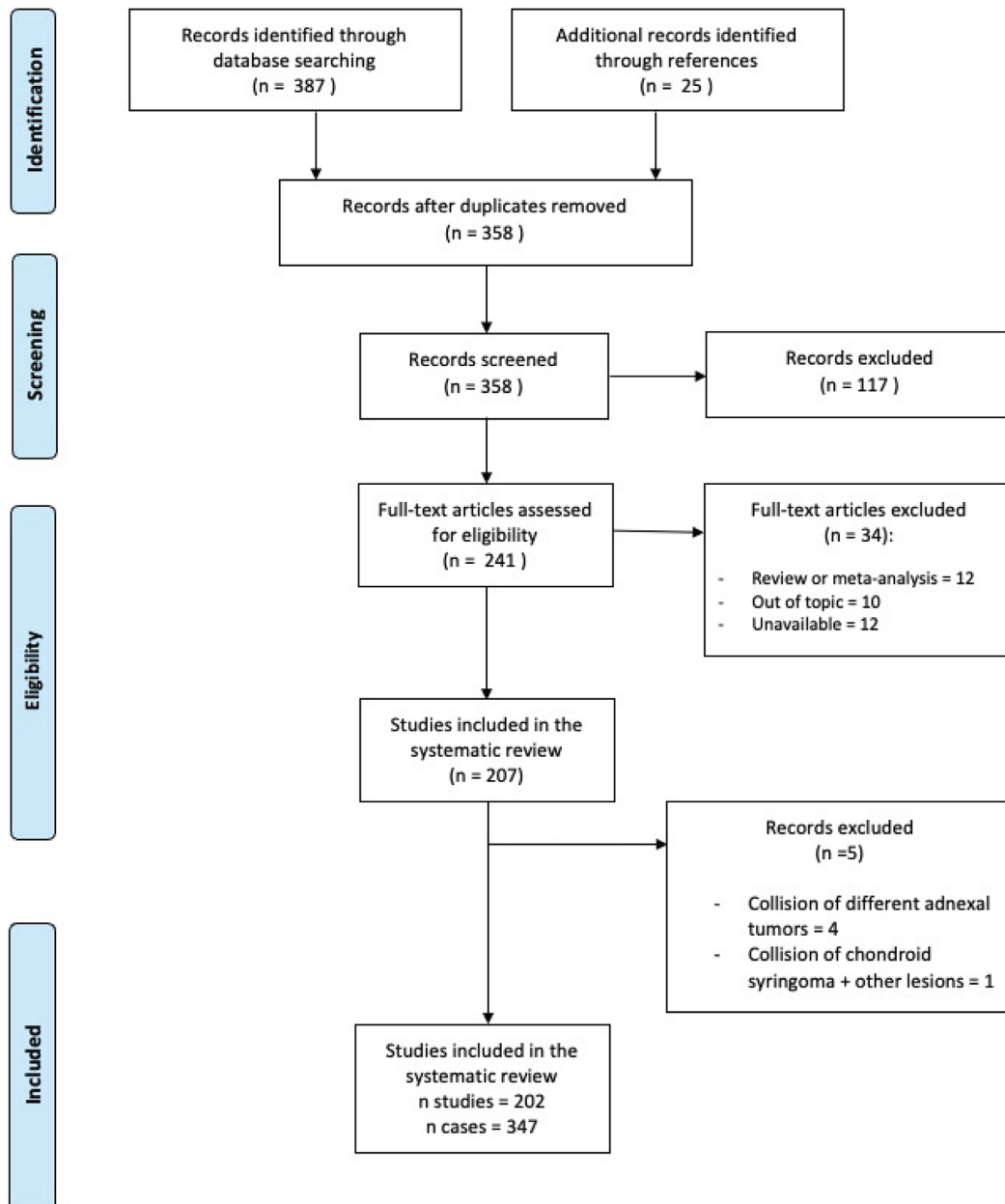


Figure S1. Flowchart of search results and study selection.

References

1. Sundling RA, So E, Logan DB. Chondroid Syringoma. *Foot Ankle Spec*. 2017 Apr;10(2):167-169. doi: 10.1177/1938640016666927. Epub 2016 Sep 20. PMID:27587378.
2. Matsuyama A, Hisaoka M, Hashimoto H. PLAG1 expression in cutaneous mixed tumors: an immunohistochemical and molecular genetic study. *Virchows Arch*. 2011 Nov;459(5):539-45. doi: 10.1007/s00428-011-1149-z. Epub 2011 Sep 17. PMID: 21927843.
3. Borman H, Deniz LM, Ertas NM, Arikan U, Colak A. Chondroid syringoma of the hand. *Scand J Plast Reconstr Surg Hand Surg*. 2009;43(5):291-3. doi: 10.3109/02844310701510330. PMID: 19863434.
4. Gottschalk-Sabag S, Glick T. Chondroid syringoma diagnosed by fine-needle aspiration: a case report. *Diagn Cytopathol*. 1994;10(2):152-5. doi:10.1002/dc.2840100211. PMID: 8187595.
5. Skoro M, Ostrović KT, Cikara I, Müller D, Novak NP, Virag M. Fine needle aspiration cytology of chondroid syringoma. *Coll Antropol*. 2010 Jun;34(2):687-90. PMID: 20698155.
6. O'Rourke MA, Cannon PS, Shaw JF, Irion LC, McKelvie PA, McNab AA. Cutaneous pleomorphic adenoma of the periorcular region - a case series. *Orbit*. 2022 Jun;41(3):361-364. doi: 10.1080/01676830.2020.1856884. Epub 2020 Dec 8. PMID: 33292052.
7. Agrawal A, Kumar A, Sinha AK, Kumar B, Sabira KC. Chondroid syringoma. *Singapore Med J*. 2008 Feb;49(2):e33-4. PMID: 18301822.
8. Aoun A, Dufrenot-Petitjean-Roget L, Amazan E, Derancourt C, Alexandre M, Quist D, Grossin M, Molinié V. Syringome chondroïde cutané [Cutaneous chondroid syringoma]. *Ann Pathol*. 2015 Aug;35(4):275-80. French. doi: 10.1016/j.annpat.2015.04.002. Epub 2015 Jul 16. PMID: 26188668.
9. Markou K, Karasmanis I, Vlachtsis K, Petridis D, Nikolaou A, Vital V. Primary pleomorphic adenoma of the external ear canal. Report of a case and literature review. *Am J Otolaryngol*. 2008 Mar-Apr;29(2):142-6. doi: 10.1016/j.amjoto.2007.04.005. PMID: 18314029.
10. Satter EK, Graham BS. Chondroid syringoma. *Cutis*. 2003 Jan;71(1):49-52, 55. PMID: 12553630.
11. Devine P, Sarno RC, Ucci AA. Malignant cutaneous mixed tumor. *Arch Dermatol*. 1984 May;120(5):576-7. doi: 10.1001/archderm.120.5.576b. PMID: 6326689.
12. Dissanayake RV, Salm R. Sweat-gland carcinomas: prognosis related to histological type. *Histopathology*. 1980 Jul;4(4):445-66. doi: 10.1111/j.1365-2559.1980.tb02939.x. PMID: 6253380.
13. Shvili D, Rothem A. Fulminant metastasizing chondroid syringoma of the skin. *Am J Dermatopathol*. 1986 Aug;8(4):321-5. doi: 10.1097/00000372-198608000-00008. PMID: 3021016.
14. Ismail D, Langman G, Orpin SD. A diagnostic challenge. *Dermatol Online J*. 2016 Nov 15;22(11):13030/qt99p6m1s2. PMID: 28329573.
15. Kisova D, Dikov T, Ivanova V, Stoyanov H, Yordanova G. Mixed Eccrine Cutaneous Tumor with Folliculo-Sebaceous Differentiation: Case Report and Literature Review. *Medicina (Kaunas)*. 2023 Aug 16;59(8):1465. doi: 10.3390/medicina59081465. PMID: 37629755; PMCID: PMC10456404.
16. Park SH, Kang SG, Choi HJ. Chondroid Syringoma of a Cheek. *J Craniofac Surg*. 2017 Jul;28(5):e480-e481. doi: 10.1097/SCS.0000000000003689. PMID: 28582289.
17. Ogawa R, Akaishi S, Hyakusoku H. Differential and exclusive diagnosis of diseases that resemble keloids and hypertrophic scars. *Ann Plast Surg*. 2009 Jun;62(6):660-4. doi: 10.1097/SAP.0b013e31817e9d67. PMID: 19461281.
18. Sun TB, Chien HF, Huang SF, Shih TT, Chen MT. Malignant chondroid syringoma. *J Formos Med Assoc*. 1996 Jul;95(7):575-8. PMID: 8840764.
19. Barnett MD, Wallack MK, Zuretti A, Mesia L, Emery RS, Berson AM. Recurrent malignant chondroid syringoma of the foot: a case report and review of the literature. *Am J Clin Oncol*. 2000 Jun;23(3):227-32. doi: 10.1097/00000421-200006000-00003. PMID: 10857882.
20. Panagopoulos I, Gorunova L, Andersen K, Lund-Iversen M, Lobmaier I, Micci F, Heim S. *NRG1-PLAG1* and *TRPS1-PLAG1* Fusion Genes in Chondroid Syringoma. *Cancer Genomics Proteomics*. 2020 May-Jun;17(3):237-248. doi: 10.21873/cgp.20184. PMID: 32345665; PMCID: PMC7259886.
21. Russell-Goldman E, Dubuc A, Hanna J. Differential Expression of PLAG1 in Apocrine and Eccrine Cutaneous Mixed Tumors: Evidence for Distinct Molecular Pathogenesis. *Am J Dermatopathol*. 2020 Apr;42(4):251-257. doi: 10.1097/DAD.0000000000001393. PMID: 30839344.
22. Sungur N, Uysal A, Gümüş M, Koçer U. An unusual chondroid syringoma. *Dermatol Surg*. 2003 Sep;29(9):977-9. PMID: 12930345.
23. Linares González L, Aguayo Carreras P, Rueda Villafranca B, Navarro-Triviño FJ. Chondroid Syringoma Mimicking Basal Cell Carcinoma. *Actas Dermosifiliogr (Engl Ed)*. 2020 May;111(4):341-343. English, Spanish. doi:10.1016/j.ad.2018.10.023. Epub 2019 May 25. PMID: 31138414.
24. He L, Vandergriff T. Apocrine mixed tumor with pilomatrical differentiation. *J Cutan Pathol*. 2021 Nov;48(11):1427-1429. doi: 10.1111/cup.14103. Epub 2021 Jul 29. PMID: 34291474.
25. Bahrami A, Dalton JD, Krane JF, Fletcher CD. A subset of cutaneous and soft tissue mixed tumors are genetically linked to their salivary gland counterpart. *Genes Chromosomes Cancer*. 2012 Feb;51(2):140-8. doi: 10.1002/gcc.20938. Epub 2011 Oct 28. PMID: 22038920; PMCID: PMC3233652.
26. Limaïem F, Bouslama S, Haddad I, Ben Slama S, Bouraoui S, Lahmar A, Mzabi-Regaya S. Chondroid syringoma: report of four cases. *Skinmed*. 2015 Mar-Apr;13(2):104-6. PMID: 26137735.
27. Agarwal R, Kulhria A, Singh K, Agarwal D. Cytodiagnosis of chondroid syringoma-Series of three cases. *Diagn Cytopathol*. 2021 Sep;49(9):E374-E377. doi: 10.1002/dc.24818. Epub 2021 Jun 26. PMID: 34174020.
28. Hong JJ, Elmore JF, Drachenberg CI, Jacobs MC, Salazar OM. Role of radiation therapy in the management of malignant chondroid syringoma. *Dermatol Surg*. 1995 Sep;21(9):781-5. doi: 10.1111/j.1524-4725.1995.tb00296.x. PMID: 7655797.
29. Wenig BM, Hitchcock CL, Ellis GL, Gnepp DR. Metastasizing mixed tumor of salivary glands. A clinicopathologic and flow cytometric analysis. *Am J Surg Pathol*. 1992 Sep;16(9):845-58. doi: 10.1097/00000478-199209000-00003. PMID: 1384375.
30. Scott A, Metcalf JS. Cutaneous malignant mixed tumor. Report of a case and review of the literature. *Am J Dermatopathol*. 1988 Aug;10(4):335-42. doi: 10.1097/00000372-198808000-00009. PMID: 2458054.
31. Lal K, Morrell TJ, Cunningham M, O'Donnell P, Levin NA, Cornejo KM. A Case of a Malignant Cutaneous Mixed Tumor (Chondroid Syringoma) of the Scapula Treated With Staged

- Margin-Controlled Excision. *Am J Dermatopathol*. 2018 Sep;40(9):679-681. doi: 10.1097/DAD.0000000000001131. PMID: 29533281.
32. Sivamani R, Wadhera A, Craig E. Chondroid syringoma: case report and review of the literature. *Dermatol Online J*. 2006 Sep 8;12(5):8. PMID: 16962023.
 33. Palioura S, Jakobiec FA, Zakka FR, Iwamoto M. Pleomorphic adenoma (formerly chondroid syringoma) of the eyelid margin with a pseudocystic appearance. *Surv Ophthalmol*. 2013 Sep-Oct; 58(5):486-91. doi: 10.1016/j.survophthal.2012.10.003. Epub 2013 Jan 4. PMID: 23294914.
 34. Bhargava D, Bhusnurmath S, Daar AS. Chondroid syringoma of the nose: report of a case. *J Laryngol Otol*. 1997 Sep;111(9): 862-4. doi: 10.1017/s0022215100138824. PMID: 9373555.
 35. Okay E, Ozkan K, Yildirim ANT, Demiroglu M, Zenginkinet T. Chondroid syringoma in an unusual localization: A case report. *Hand Surg Rehabil*. 2021 Jun;40(3):353-354. doi: 10.1016/j.hansur.2020.12.015. Epub 2021 Feb 25. PMID: 33640518.
 36. Agrawal V, Gupta RL, Kumar S, Mishra K, Agarwal S. Malignant chondroid syringoma. *J Dermatol*. 1998 Aug;25(8):547-9. doi: 10.1111/j.1346-8138.1998.tb02453.x. PMID: 9769603.
 37. Smiri KH, Fenniche S, Marrak H, Daoud L, Debliche A, Ben Ayed M, Mokhtar I. Le syringome chondroïde [Chondroid syringoma]. *Tunis Med*. 2005 Jun;83(6):372-4. French. PMID: 16156416.
 38. Yavuzer R, Başterzi Y, Sari A, Bir F, Sezer C. Chondroid syringoma: a diagnosis more frequent than expected. *Dermatol Surg*. 2003 Feb;29(2):179-81. doi: 10.1046/j.1524-4725.2003.29045.x. PMID: 12562350.
 39. Wollina U, Sturm U, Schönlebe J. Benign chondroid syringoma (mixed tumor of skin) on the flank with satellites: case report and literature review. *Wien Med Wochenschr*. 2014 Sep;164(17-18): 377-80. doi: 10.1007/s10354-014-0302-0. Epub 2014 Oct 1. Erratum in: *Wien Med Wochenschr*. 2014 Oct;164(19-20):446. PMID: 25271109.
 40. Franco JP, Zaccaron LH, Lima RB, D'Acri AM, Martins CJ. Case for diagnosis. Chondroid syringoma. *An Bras Dermatol*. 2013 Nov-Dec;88(6):997-9. doi: 10.1590/abd1806-4841.20132515. PMID: 24474117; PMCID: PMC3900359.
 41. Jun HJ, Cho E, Cho SH, Lee JD. Chondroid syringoma with marked calcification. *Am J Dermatopathol*. 2012 Dec;34(8):e125-7. doi: 10.1097/DAD.0b013e31824c2202. PMID: 23169420.
 42. Zirbs M, Konstantinow A, Ziai M, Brockow K, Hein R, Ring J. Mischttumor der Haut [Mixed tumor of the skin]. *Hautarzt*. 2011 Sep;62(9):688-90. German. doi: 10.1007/s00105-010-2103-8. PMID: 21258775.
 43. Purkayastha P, Thomson R, Wilson Jones N, Ng S. Chondroid syringoma: an unusual presentation in a 7-year-old boy. *BMJ Case Rep*. 2021 Jul 26;14(7):e232943. doi: 10.1136/bcr-2019-232943. PMID: 34312123; PMCID: PMC8314740.
 44. Villalón G, Monteagudo C, Martín JM, Ramón D, Alonso V, Jordá E. Siringoma condroïde: revisión clínica e histológica de ocho casos [Chondroid syringoma: a clinical and histological review of eight cases]. *Actas Dermosifiliogr*. 2006 Nov;97(9):573-7. Spanish. doi: 10.1016/s0001-7310(06)73468-8. PMID: 17173760.
 45. Hudson LE, Craven CM, Wojno TH, Grossniklaus HE. Giant Chondroid Syringoma of the Lower Eyelid. *Ophthalmic Plast Reconstr Surg*. 2017 Mar/Apr;33(2):e43-e44. doi: 10.1097/IOP.0000000000000716. PMID: 27203613; PMCID: PMC5116295.
 46. An I, Harman M, Ibiloglu I. Asymptomatic flesh-colored lobular nodule on the nose. *Dermatol Online J*. 2018 Feb 15;24(2): 13030/qt9zk7j85m. PMID: 29630154.
 47. Ungureanu I, Delcourt T, Perret R, Denoux Y. Tumeurs myoépithéliales des tissus mous : à propos d'un cas de tumeur mixte [Myoepithelial tumors of soft tissue: A case of mixed tumor]. *Ann Patol*. 2023 Nov;43(6):479-482. French. doi: 10.1016/j.annpat.2023.02.008. Epub 2023 Mar 9. PMID: 36906453.
 48. Madi K, Attanasio A, Cecunjanin F, Garcia RA, Vidershayn A, Lucido JV. Chondroid Syringoma of the Foot: A Rare Diagnosis. *J Foot Ankle Surg*. 2016 Mar- Apr;55(2):373-8. doi: 10.1053/j.jfas.2014.12.032. Epub 2015 May 23. PMID: 26015300.
 49. Prajapati CK, Mehta MJ, Kunikullaya US. Chondroid syringoma of an upper eyelid tumor: Unusual case report. *Indian J Cancer*. 2023 Apr-Jun;60(2):245-247. doi: 10.4103/ijc.IJC_164_21. PMID: 36861706.
 50. Mandeville JT, Roh JH, Woog JJ, Gonnering RS, Levin PS, Mazzoli RA, Ainbinder DJ, Older JJ, Moulin AP, Kiel R, Kim YD, Dryja TP. Cutaneous benign mixed tumor (chondroid syringoma) of the eyelid: clinical presentation and management. *Ophthalmic Plast Reconstr Surg*. 2004 Mar;20(2):110-6. doi: 10.1097/01.iop.0000117337.65340.e5. PMID: 15083078.
 51. Tyagi N, Abdi U, Tyagi SP, Maheshwari V, Gogi R. Pleomorphic adenoma of skin (chondroid syringoma) involving the eyelid. *J Postgrad Med*. 1996 Oct- Dec;42(4):125-6. PMID: 9715316.
 52. Yaakub A, Varma S, Kulkarni K, Batchelor J. A recurring nodule on the nose. *Clin Exp Dermatol*. 2013 Mar;38(2):205-6. doi: 10.1111/j.1365-2230.2012.04344.x. Epub 2012 Mar 22. PMID: 22439813.
 53. Charles NC, Patel P. Eyebrow madarosis reflecting an intra-dermal neoplasm: pleomorphic adenoma, a rare brow tumour. *Can J Ophthalmol*. 2016 Jun;51(3):e84-5. doi: 10.1016/j.cjco.2016.01.013. Epub 2016 Apr 28. PMID: 27316286.
 54. Yamamoto O, Yasuda H. An immunohistochemical study of the apocrine type of cutaneous mixed tumors with special reference to their follicular and sebaceous differentiation. *J Cutan Pathol*. 1999 May;26(5):232-41. doi: 10.1111/j.1600-0560.1999.tb01836.x. PMID: 10408348.
 55. Miracco C, De Santi MM, Lalinga AV, Pellegrino M, Schürfeld K, Sbrano P, Miracco F. Lipomatous mixed tumour of the skin: a histological, immunohistochemical and ultrastructural study. *Br J Dermatol*. 2002 May;146(5):899-903. doi: 10.1046/j.1365-2133.2002.04645.x. PMID: 12000393.
 56. Choi HJ, Son ET, Lee HJ. Chondroid syringoma of the nasal dorsum. *J Craniofac Surg*. 2015 Jan;26(1):e12-4. doi: 10.1097/SCS.0000000000001222. PMID: 25565228.
 57. Odhav A, Odhav C, Odhav S. Diagnosis of a rapidly growing preauricular nodule: chondroid syringoma or pleomorphic adenoma? *Cutis*. 2016 Oct;98(4):E7-E9. PMID: 27874890.
 58. Petrović A, Cerfalvi V, Tomas D, Stephany Kirigin M, Krušlin B. Atypical Mixed Tumor of the Skin in the Gluteal Region with Strong and Diffuse Nuclear Expression of the p16 Stain: A Case Report. *Acta Dermatovenerol Croat*. 2022 Nov;30(3):163-165. PMID: 36812274.
 59. Steinmetz JC, Russo BA, Ginsburg RE. Malignant chondroid syringoma with widespread metastasis. *J Am Acad Dermatol*. 1990 May;22(5 Pt 1):845-7. doi: 10.1016/s0190-9622(08)81178-4. PMID: 2161437.
 60. Medina Henriquez JA, Navarro Garcia R, Nagel D, Foucher G. Malignant chondroid syringoma of the hand: a case report.

- Scand J Plast Reconstr Surg Hand Surg.* 2001 Dec;35(4):437-9. doi: 10.1080/028443101317149435. PMID: 11878183.
61. Rogers R, Zhou F, Grunes D, Shapiro RL, Bannan M, Simsir A, Leung A. Chondroid syringoma of the axilla: An unusual tumor diagnosed by fine needle aspiration. *Diagn Cytopathol.* 2016 Apr;44(4):342-6. doi: 10.1002/dc.23424. Epub 2016 Jan 22. PMID: 26800260.
 62. Shalini B, Akshi K, Namrata N, Shilpi S, Manupriya N. Case of chondroid syringoma mimicking a nodular hidradenoma: A diagnostic pitfall on cytopathology. *Diagn Cytopathol.* 2018 Jan;46(1):59-62. doi: 10.1002/dc.23791. Epub 2017 Aug 3. Erratum in: *Diagn Cytopathol.* 2018 Jul;46(7):645. PMID: 28772003.
 63. Masamatti SS, Vijaya C, Narasimha A. A rare case of hyaline cell-rich atypical chondroid syringoma with divergent differentiation. *Indian J Pathol Microbiol.* 2018 Jul-Sep;61(3):428-430. doi: 10.4103/IJPM.IJPM_101_17. PMID:30004073.
 64. Rosell-Díaz ÁM, Barchino-Ortiz L, Pulido-Pérez A, Parra-Blanco V, Requena L, Vilas Boas P. *Dermpath & Clinic: Mixed tumour of the skin.* *Eur J Dermatol.* 2020 Feb 1;30(1):73-75. doi: 10.1684/ejd.2020.3733. PMID: 32250265.
 65. Ki SY, Lim HS, Lee HJ, Lee JS. Chondroid syringoma of the axilla masquerading as a metastatic lymph node. *Breast J.* 2020 Jul;26(7):1402-1403. doi: 10.1111/tbj.13773. Epub 2020 Feb 7. PMID: 32034830.
 66. Chauvel-Picard J, Pierrefeuf A, Harou O, Breton P, Sigaux N. Unusual cystic lesion of the eyebrow: A case report of malignant chondroid syringoma. *J Stomatol Oral Maxillofac Surg.* 2018 Jun;119(3):232-235. doi: 10.1016/j.jormas.2018.02.008. Epub 2018 Feb 22. PMID: 29477759.
 67. Miranda JA, Mazzotta MM, Zalazar ÉV. Malignant Chondroid Syringoma of the Face With Distant Metastasis. *Actas Dermosifiliogr.* 2023 Jul-Aug;114(7):652-654. English, Spanish. doi: 10.1016/j.ad.2022.01.049. Epub 2022 Sep 14. PMID: 36113611.
 68. Kuwabara H, Haginomori S, Takamaki A, Ito K, Takenaka H, Kurisu Y, Tsuji M, Mori H. Lipomatous pleomorphic adenoma of the ceruminous gland. *Pathol Int.* 2006 Jan;56(1):51-3. doi: 10.1111/j.1440-1827.2006.01918.x. PMID: 16398681.
 69. Zia S, Shaw B, Chapman S, Friedman BJ. An atypical chondroid syringoma with malignant degeneration: Utility of comparative genomic hybridization in confirming the diagnosis. *J Cutan Pathol.* 2021 Jun;48(6):775-780. doi: 10.1111/cup.13965. Epub 2021 Feb 1. PMID: 33470448.
 70. Kumar B. Chondroid syringoma diagnosed by fine needle aspiration cytology. *Diagn Cytopathol.* 2010 Jan;38(1):38-40. doi: 10.1002/dc.21159. PMID: 19693940.
 71. GREELEY PW, GLEASON MC, CURTIN JW. Mixed cell tumors of the skin. *Plast Reconstr Surg (1946).* 1956 Dec;18(6):427-35. doi: 10.1097/00006534-195612000-00002. PMID: 13408115.
 72. Nguyen CM, Cassarino DS. Local recurrence of cutaneous mixed tumor (chondroid syringoma) as malignant mixed tumor of the thumb 20 years after initial diagnosis. *J Cutan Pathol.* 2017 Mar;44(3):292-295. doi: 10.1111/cup.12884. Epub 2017 Feb 2. PMID: 28035707.
 73. Rege J, Shet T. Aspiration cytology in the diagnosis of primary tumors of skin adnexa. *Acta Cytol.* 2001 Sep-Oct;45(5):715-22. doi: 10.1159/000328293. PMID: 11575649.
 74. Lennox B, Pearse AG, Richards HG. Mucin-secreting tumours of the skin with special reference to the so-called mixed-salivary tumour of the skin and its relation to hidradenoma. *J Pathol Bacteriol.* 1952 Oct;64(4):865-80. doi: 10.1002/path.1700640418. PMID: 13000598.
 75. Phelps PO, Potter HD, Lucarelli MJ. Apocrine Chondroid Syringoma of the Eyelid. *Ophthalmology.* 2015 Jul;122(7):1415. doi: 10.1016/j.ophtha.2015.02.027. PMID: 26711479.
 76. Sereflican B, Kizildag B, Kurt OK, Sereflican M, Goksugur N, Boran C. Giant Chondroid Syringoma of the Breast. *Breast J.* 2015 Jul-Aug;21(4):438-9. doi: 10.1111/tbj.12421. Epub 2015 Apr 27. PMID: 25919351.
 77. Whittle C, Mackinnon J, Cabrera R, Silva C, Pires Y, González R. Finger chondroid syringoma as a hypoechoic subcutaneous nodule in ultrasound. *Ultrasound Q.* 2013 Sep;29(3):211-3. doi: 10.1097/RUQ.0b013e3182a1bf7d. PMID:23945489.
 78. Abil S, Bouhllab J, Zarkik S, Lamchahab FZ, Saidi A, Ismaili N, Senouci K, Hassam B. Syringome chondroïde de la face [Chondroid syringoma of the face]. *Ann Dermatol Venereol.* 2012 Oct;139(10):681-3. French. doi: 10.1016/j.annder.2012.04.149. Epub 2012 Jun 2. PMID: 23122384.
 79. Hardisson D, Linares MD, Nistal M. Giant chondroid syringoma of the axilla. *J Cutan Med Surg.* 1998 Oct;3(2):115-7. doi: 10.1177/120347549800300214. PMID: 9822789.
 80. Boyaci N, Boyaci A, Karakas O, Karakaş E, Yildiz S, Kocarslan S. Giant benign Chondroid Syringoma in the elbow. *Clin Ter.* 2014;165(4):207-9. doi: 10.7417/CT.2014.1735. PMID: 25203335.
 81. Kau HC, Tsai CC. Giant chondroid syringoma of the eyelid. *Can J Ophthalmol.* 2013 Aug;48(4):e63-4. doi: 10.1016/j.cjco.2013.01.012. PMID: 23931483.
 82. Vázquez Hernández A, Pérez Campos AE, Gamboa Jiménez TI, Fenton Navarro BF. Giant chondroid syringoma on the upper lip: a case report. *Dermatol Online J.* 2021 May 15;27(5). doi: 10.5070/D327553622. PMID: 34118822.
 83. Kumar MA, Srikanth K, Vathsalya R. Chondroid syringoma: a rare lid tumor. *Indian J Ophthalmol.* 2013 Jan-Feb;61(1):43-4. doi: 10.4103/0301-4738.105060. PMID: 23275227; PMCID: PMC3555002.
 84. Kothiya M, Mittal N, Kumar R, Kane S. Malignant chondroid syringoma of thigh with late metastasis to lung: A very rare case report. *Indian J Pathol Microbiol.* 2017 Jul-Sep;60(3):418-420. doi: 10.4103/IJPM.IJPM_322_16. PMID: 28937387.
 85. Turhan-Haktanir N, Sahin O, Bukulmez A, Demir Y. Chondroid syringoma in a child. *Pediatr Dermatol.* 2007 Sep-Oct;24(5):505-7. doi: 10.1111/j.1525-1470.2007.00504.x. PMID: 17958797.
 86. Radhi JM. Chondroid syringoma with small tubular lumina. *J Cutan Med Surg.* 2004 Jan-Feb;8(1):23-4. doi: 10.1007/s10227-003-0107-z. Epub 2004 Jan 23. PMID:14735396.
 87. Reis-Filho JS, Silva P, Milanezi F, Lopes JM. Hyaline cell-rich chondroid syringoma: case report and review of the literature. *Pathol Res Pract.* 2002;198(11):755-64. doi: 10.1078/0344-0338-00332. PMID: 12530579.
 88. Bisceglia M, Clemente CR, Vairo M, Cafaro A, Pasquinelli G. "Siringoma condroide a cellule ialine." Studio morfologico, immunoistochimico e ultrastrutturale di un caso e revisione della letteratura ["Hyaline-cell chondroid syringoma." Morphological, immunohistochemical and ultrastructural study of a case and review of the literature]. *Pathologica.* 1997 Oct;89(5):540-5. Italian. PMID: 9489403.
 89. Nicolaou S, Dubec JJ, Munk PL, O'Connell JX, Lee MJ. Malignant chondroid syringoma of the skin: magnetic resonance imaging features. *Australas Radiol.* 2001 May;45(2):240-3. doi: 10.1046/j.1440-1673.2001.00912.x. PMID: 11380374.

90. Nakanishi A, Honoki K, Omokawa S, Tanaka Y. Malignant Mixed Tumor of the Finger: A Case Report. *J Hand Surg Asian Pac* Vol. 2018 Jun;23(2):286-289. doi: 10.1142/S2424835518720190. PMID: 29734892.
91. Lu H, Chen LF, Chen Q, Shen H, Liu Z. A rare large cutaneous chondroid syringoma involving a toe: A case report. *Medicine (Baltimore)*. 2018 Feb;97(5):e9825. doi: 10.1097/MD.00000000000009825. PMID: 29384887; PMCID: PMC5805459.
92. Torii H, Nakagawa H, Ishibashi Y. So-called mixed tumor of the skin on the wrist: an immunohistochemical study. *J Dermatol*. 1995 Mar;22(3):213-7. doi: 10.1111/j.1346-8138.1995.tb03374.x. PMID: 7537769.
93. Wernham A, Smith H, Patel A, Varma S, Lam M. Chondroid syringoma of the heel masquerading as a malignant tumour: A potential pitfall in diagnosis. *Australas J Dermatol*. 2020 Feb;61(1):60-61. doi: 10.1111/ajd.13097. Epub 2019 Jun 25. PMID: 31237677.
94. Nemoto K, Kato N, Arino H. Chondroid syringoma of the hand. *Scand J Plast Reconstr Surg Hand Surg*. 2002;36(6):379-81. doi: 10.1080/028443102321096401. PMID: 12564820.
95. Park SM, Ko HC, Kim BS, Kim MB, Mun JH. Large protruding telangiectatic nodule on the nose. *Clin Exp Dermatol*. 2015 Jun;40(4):460-2. doi: 10.1111/ced.12511. Epub 2014 Dec 5. PMID: 25476592.
96. Nakayama H, Miyazaki E, Hiroi M, Kiyoku H, Naruse K, Enzan H. So-called neoplastic myoepithelial cells in chondroid syringomas/mixed tumors of the skin: their subtypes and immunohistochemical analysis. *Pathol Int*. 1998 Apr;48(4):245-53. doi: 10.1111/j.1440-1827.1998.tb03902.x. PMID: 9648152.
97. Dubb M, Michelow P. Cytologic features of chondroid syringoma in fine needle aspiration biopsies: a report of 3 cases. *Acta Cytol*. 2010 Mar-Apr;54(2):183-6. doi: 10.1159/000325005. PMID: 20391975.
98. Siddaraju N, Murugan P, Wilfred CD, Choudhury N, Basu D. Preoperative cytologic diagnosis of chondroid syringoma. *Acta Cytol*. 2009 Sep-Oct;53(5):607-10. doi: 10.1159/000325396. PMID: 19798896.
99. Kakuta M, Tsuboi R, Yamazaki M, Sakuma M, Yoshikata R, Ogawa H. Giant mixed tumor of the face. *J Dermatol*. 1996 May;23(5):369-71. doi: 10.1111/j.1346-8138.1996.tb04034.x. PMID: 8675832.
100. Kerimoglu U, Aydingoz U, Ozkaya O, Aksu AE, Ergen FB. MRI of a benign chondroid syringoma. *Br J Radiol*. 2006 Aug;79(944):e59-61. doi: 10.1259/bjr/14399042. PMID: 16861320.
101. Eccher A, Brunelli M, Gobbo S, Dalfior D, Dvornik G, Barbareschi M, Parolini C, Menestrina F, Martignoni G. Chondroid syringoma with extensive ossification. *Int J Surg Pathol*. 2007 Oct;15(4):385-7. doi: 10.1177/1066896907306126. PMID: 17913946.
102. Poku JW, Sant GR, Ucci AA. Chondroid syringoma of the scrotum. *J Int Med Res*. 1996 Nov-Dec;24(6):482-6. doi: 10.1177/030006059602400606. PMID: 8959533.
103. Gündüz K, Demirel S, Heper AO, Günalp I. A rare case of atypical chondroid syringoma of the lower eyelid and review of the literature. *Surv Ophthalmol*. 2006 May-Jun;51(3):280-5. doi: 10.1016/j.survophthal.2006.02.001. PMID: 16644368.
104. Hafezi-Bakhtiari S, Al-Habeeb A, Ghazarian D. Benign mixed tumor of the skin, hypercellular variant: a case report. *J Cutan Pathol*. 2010 Sep;37(9):e46-9. doi: 10.1111/j.1600-0560.2009.01329.x. Epub 2009 Jul 10. PMID: 19614993.
105. Chen AH, Moreano EH, Houston B, Funk GF. Chondroid syringoma of the head and neck: clinical management and literature review. *Ear Nose Throat J*. 1996 Feb;75(2):104-8. PMID: 8714424.
106. Kelten C, Boyaci C, Trabulus DC, Sirin S. Benign mixed tumour of the breast and breast skin, two cases with diagnostic difficulties. *BMJ Case Rep*. 2015 Jun 29;2015:bcr2015210906. doi: 10.1136/bcr-2015-210906. PMID: 26123472; PMCID: PMC4488656.
107. Mencía-Gutiérrez E, Bonales-Daimiel JA, Gutiérrez-Díaz E, Santos-Briz A, Madero-García S. Chondroid syringomas of the eyelid: two cases. *Eur J Ophthalmol*. 2001 Jan-Mar;11(1):80-2. doi: 10.1177/112067210101100116. PMID: 11284492.
108. Jain A, Arava S. Chondroid syringoma with extensive cystic change and focal syringometaplasia: A rare histomorphological finding. *Indian J Pathol Microbiol*. 2018 Jan-Mar;61(1):143-144. doi: 10.4103/IJPM.IJPM_539_16. PMID: 29567907.
109. Varsori M, Dettwiler S, Chaloupka K. Syringome chondroïde de la paupière: à propos d'un cas [Eyelid chondroid syringoma: a case report]. *J Fr Ophtalmol*. 2007 Jan;30(1):e3. French. doi: 10.1016/s0181-5512(07)89556-8. PMID: 17287665.
110. Arango-Duque LC, Yuste-Chaves M, Rodríguez-González M. Asymptomatic lesion on the nasal ala. *Actas Dermosifiliogr*. 2012 Nov;103(9):827-8. English, Spanish. doi: 10.1016/j.ad.2012.04.009. Epub 2012 Jul 5. PMID: 22770897.
111. Laxmisha C, Thappa DM, Jayanthi S. Chondroid syringoma of the ear lobe. *J Eur Acad Dermatol Venereol*. 2007 Feb; 21(2):276-7. doi: 10.1111/j.1468-3083.2006.01848.x. PMID: 17243982.
112. Chao PZ, Lee FP. Pleomorphic adenoma (chondroid syringoma) on the face. *Otolaryngol Head Neck Surg*. 2004 Apr;130(4):499-500. doi: 10.1016/j.otohns.2003.07.012. PMID: 15100654.
113. Sirivella S, Gielchinsky I. Chondroid syringoma: a rare tumor of the chest wall. *Ann Thorac Surg*. 2010 Mar;89(3):983-5. doi: 10.1016/j.athoracsur.2009.07.062. PMID: 20172178.
114. Araújo JL, de Aguiar GB, do Prado Aguiar U, Mayrink D, Saade N, Veiga JC. Malignant chondroid syringoma with central nervous system involvement. *J Craniofac Surg*. 2012 Mar;23(2): 514-5. doi: 10.1097/SCS.0b013e31824cd493. PMID: 22421860.
115. Owen JL, Amin S, Liu W, Chaudhari R, Guitart J, Ahmad A, Krunic AL. Giant chondroid syringomas: Review of surgical challenges and treatment approaches, including excision, enucleation and Mohs micrographic surgery. *Australas J Dermatol*. 2020 May;61(2):173-176. doi: 10.1111/ajd.13204. Epub 2019 Nov 21. PMID: 31755087.
116. Mahindra Nayyar P, Mazza J, Ratner D. Rapidly growing erythematous nodule of the right cheek. *Dermatol Surg*. 2015 Feb;41(2):289-91. doi: 10.1097/DSS.0000000000000263. PMID: 25654201.
117. Sheikh SS, Pennanen M, Montgomery E. Benign chondroid syringoma: report of a case clinically mimicking a malignant neoplasm. *J Surg Oncol*. 2000 Apr;73(4):228-30. doi: 10.1002/(sici)1096-9098(200004)73:4<228::aid-jso8>3.0.co;2-m. PMID: 10797337.
118. Awasthi R, Harmse D, Courtney D, Lyons CB. Benign mixed tumour of the skin with extensive ossification and marrow formation: a case report. *J Clin Pathol*. 2004 Dec;57(12):1329-30. doi: 10.1136/jcp.2004.020172. PMID: 15563678; PMCID: PMC1770529

119. Rogalski B, Nahmias ZP, Phelan PS, Rosman I, Council ML. A Case Report of Chondroid Syringoma on the Nose in a Young Male of Middle Eastern Descent. *J Cutan Med Surg*. 2019 Jan/Feb;23(1):99-101. doi: 10.1177/1203475418791558. Epub 2018 Jul 24. PMID: 30041541.
120. Requena C, Brotons S, Sanmartín O, Llombart B, Traves V, Guillén C, Requena L. Malignant chondroid syringoma of the face with bone invasion. *Am J Dermatopathol*. 2013 May;35(3):395-8. doi: 10.1097/DAD.0b013e318274393d. PMID: 23095341.
121. Zumdick M, Milde P, Ruzicka T, Hölzle E. Apokriner kutaner Misch tumor mit follikulärer Differenzierung [Cutaneous apocrine mixed tumor with follicular differentiation]. *Hautarzt*. 1995 Jul;46(7):481-4. German. doi: 10.1007/s001050050286. PMID: 7672988.
122. Alfonso Fernández A, de la Red Gallego MA, Pérez Carro L. Chondroid syringoma invading the distal phalanx of the thumb: a case report. *J Hand Surg Eur Vol*. 2017 May;42(4):426-427. doi: 10.1177/1753193416644590. Epub 2016 Apr 18. PMID: 27090725.
123. Menéndez RH, Erice SG, Bas CA, Casas G, Dillon HS. Spinal cord compression secondary to metastasis of malignant chondroid syringoma: case report. *J Neurosurg Spine*. 2015 Mar;22(3):310-3. doi: 10.3171/2014.9.SPINE14360. Epub 2015 Jan 2. PMID: 25555054.
124. KHOO TK, TZE KB. A SWEAT GLAND TUMOUR OF THE MIXED-SALIVARY TYPE OF THE RIGHT MIDDLE TOE. *Med J Malaya*. 1964 Dec;19:128-33. PMID: 14279235.
125. Sirinoğlu H, Ersoy B, Tezel E. Benign chondroid syringoma: atypical presentation of a rare eccrine tumor. *J Foot Ankle Surg*. 2011 May- Jun;50(3):364-6. doi: 10.1053/j.jfas.2011.01.006. Epub 2011 Mar 11. PMID: 21397527.
126. Akasaka T, Onodera H, Matsuta M. Cutaneous mixed tumor containing ossification, hair matrix, and sebaceous ductal differentiation. *J Dermatol*. 1997 Feb;24(2):125-31. doi: 10.1111/j.1346-8138.1997.tb02757.x. PMID: 9065710.
127. Nangia A, Sehgal S, Pujani M, Patiri K. Chondroid syringoma with extensive osseous differentiation: a rare finding. *Indian J Pathol Microbiol*. 2014 Apr- Jun;57(2):344-5. doi: 10.4103/0377-4929.134746. PMID: 24943789.
128. Watarai A, Amoh Y, Aki R, Takasu H, Katsuoka K. Malignant chondroid syringoma: report of a case with lymph node metastasis 12 years after local excision. *Dermatol Online J*. 2011 Sep 15;17(9):5. PMID: 21971270.
129. Cýralýk H, Bülbüloğlu E, Arýcan O, Sařmaz S. A 72-year-old man with a mass in his right axilla. *Acta Dermatovenerol Alp Pannonica Adriat*. 2007 Dec;16(4):177-9. PMID: 18204750.
130. Choudhury M, Agarwal C, Aggarwal M, Pathania OP, Goel N. Clinicopathological profile of an unusual case of chondroid syringoma: a case report. *Indian J Pathol Microbiol*. 2007 Apr;50(2):349-51. PMID: 17883069.
131. Tokyol C, Aktepe F, Yavas BD, Yildiz H, Aycicek A. Chondroid syringoma: a case report. *Acta Cytol*. 2010 Sep-Oct; 54(5 Suppl):973-6. PMID: 21053580.
132. Peria M, Coste A, Prulière-Escabasse V. An atypical skin lesion. *Eur Ann Otorhinolaryngol Head Neck Dis*. 2016 Apr;133(2):141-3. doi: 10.1016/j.anorl.2015.08.012. Epub 2015 Sep 2. PMID: 26340894.
133. Kiely JL, Dunne B, McCabe M, McNicholas WT. Malignant chondroid syringoma presenting as multiple pulmonary nodules. *Thorax*. 1997 Apr;52(4):395-6. doi: 10.1136/thx.52.4.395. PMID: 9196529; PMCID: PMC1758548.
134. Paik YS, Liess BD. Chondroid syringoma of the scalp: case report and discussion of clinical features, histopathology, and treatment. *Ear Nose Throat J*. 2011 Apr;90(4):190-1. doi: 10.1177/014556131109000411. PMID: 21500172.
135. Mebazaa A, Trabelsi S, Denguezli M, Sriha B, Belajouza C, Noura R. Chondroid syringoma of the arm: an unusual localization. *Dermatol Online J*. 2006 Jan 27;12(1):14. PMID: 16638382.
136. Takahashi H, Ishiko A, Kobayashi M, Tanikawa A, Takasu H, Md MT. Malignant chondroid syringoma with bone invasion: a case report and review of the literature. *Am J Dermatopathol*. 2004 Oct;26(5):403-6. doi: 10.1097/00000372-200410000-00011. PMID: 15365374.
137. Walls AC, Deng A, Geist DE. Mohs micrographic surgery for recurrent chondroid syringoma of the eyebrow. *Dermatol Surg*. 2012 May;38(5):800-2. doi: 10.1111/j.1524-4725.2012.02353.x. Epub 2012 Feb 6. PMID: 22309155.
138. Hernandez FJ. Mixed tumors of the skin of the salivary gland type: a light and electron microscopic study. *J Invest Dermatol*. 1976 Jan;66(1):49-52. doi: 10.1111/1523-1747.ep12478101. PMID: 54394.
139. Brewer NH, Bridges MA. Chondroid syringoma of the nasal soft tissue triangle. *Otolaryngol Head Neck Surg*. 2009 Apr;140(4):606-7. doi: 10.1016/j.otohns.2008.12.030. PMID: 19328357.
140. Prieto-Granada CN, Garapati M. Cutaneous Mixed Tumor and Recurrent Laryngeal Squamous Cell Carcinoma With Tyrosine-Rich Crystalloids: The Good, the Bad, and the Pretty. *Int J Surg Pathol*. 2017 Dec;25(8):696-697. doi: 10.1177/1066896917709351. Epub 2017 May 16. PMID: 28508684.
141. Martorina M, Capoferri C, Dessanti P. Chondroid syringoma of the eyelid. *Int Ophthalmol*. 1993 Oct;17(5):285-8. doi: 10.1007/BF01007797. PMID: 8132408.
142. Tang X, Tamura Y, Tsutsumi Y. Mixed tumor of the external auditory canal. *Pathol Int*. 1994 Jan;44(1):80-3. doi: 10.1111/j.1440-1827.1994.tb02589.x. PMID: 7517760.
143. Kaushik V, Bhalla RK, Nicholson C, de Carpentier JP. The chondroid syringoma: report of a case arising from the external auditory canal. *Eur Arch Otorhinolaryngol*. 2005 Oct;262(10):868-70. doi: 10.1007/s00405-004-0912-z. Epub 2005 Mar 1. PMID: 15739085.
144. Magro G, Florida F, Geraci G, Marino B. Lipomatous apocrine mixed tumor of the skin: an unusual giant lesion occurring in the breast. *J Cutan Pathol*. 2009 Jun;36(6):692-6. doi: 10.1111/j.1600-0560.2008.01104.x. PMID: 19515050.
145. Kakitsubata Y, Theodorou SJ, Theodorou DJ, Nakahara M, Yuki Y, Yokouchi T. Giant chondroid syringoma presenting as a growing subcutaneous mass in the upper arm: MRI findings with pathologic correlation. *Joint Bone Spine*. 2009 Dec;76(6):711-4. doi: 10.1016/j.jbspin.2009.04.006. PMID: 19793672.
146. Shimizu S, Han-Yaku H, Fukushima S, Shimizu H. Immunohistochemical study of mixed tumor of the skin with marked ossification. *Dermatology*. 1996;193(3):255-7. doi: 10.1159/000246259. PMID: 8944353.
147. Mathiasen RA, Rasgon BM, Rumore G. Malignant chondroid syringoma of the face: a first reported case. *Otolaryngol*

- Head Neck Surg.* 2005 Aug;133(2):305-7. doi: 10.1016/j.otohns.2004.09.139. PMID: 16087034.
148. Kazikdas KC, Onal K, Ekinçi N. Pathology quiz case 1: Apocrine mixed tumor of the skin. *Arch Otolaryngol Head Neck Surg.* 2007 Feb;133(2):198, 200. doi: 10.1001/archotol.133.2.198. PMID: 17309993.
 149. Ryu JK, Jin W, Kim GY, Lee JH. Sonographic and magnetic resonance imaging findings of a chondroid syringoma of the heel: case report and literature review. *J Ultrasound Med.* 2007 Oct;26(10):1435-9. doi: 10.7863/jum.2007.26.10.1435. PMID: 17901146.
 150. Beals TC, Nickisch F, Teman C, Florell SR, Layfield LJ. Chondroid syringoma: case report of a highly unusual foot tumor. *Foot Ankle Int.* 2010 Apr;31(4):333-5. doi: 10.3113/FAI.2010.0333. PMID: 20371021.
 151. Solanki LS, Dhingra M, Bhalla M, Thami GP, Punia RP, Batra S. Chondroid syringoma: report of two cases in young patients. *Dermatol Online J.* 2011 Dec 15;17(12):7. PMID: 22233743.
 152. Hernandez A, Gardner J, Parker D, Monson D, Edgar M. Chondroid syringoma (mixed tumor) with tyrosine crystals. *J Cutan Patol.* 2013 Jun;40(6):527-9. doi: 10.1111/cup.12171. PMID: 23647029.
 153. Karnwal A, Pakalapati S, Tzifa K, Raut V. Chondroid syringoma of the external ear canal presenting as a cyst. *Kulak Burun Bogaz Ihtis Derg.* 2006;16(2):80-2. PMID: 16763421.
 154. Hasson O, Levy Y, Nahlieli O, Ziccardi VB. Multiple slow-growing nodules on the cheek. *J Oral Maxillofac Surg.* 2001 Jul;59(7):796-9. doi: 10.1053/joms.2001.24294. PMID: 11429743.
 155. Arikan OK, Erdoğan S, Muluk NB, Koç C. Chondroid syringoma of the upper lip: a case report. *Kulak Burun Bogaz Ihtis Derg.* 2004;13(1-2):25-7. PMID: 16027488.
 156. Ogawa R, Mitsushashi K, Oki K, Hyakusoku H. A rare case of chondroid syringoma arising from the lower eyelid with ectropion. *Plast Reconstr Surg.* 2006 Nov;118(6):137e-140e. doi: 10.1097/01.prs.0000239561.50033.45. PMID: 17051093.
 157. Gee BC, Morris AD, Kaye P, Varma S. A rare, rapidly growing purple tumor on the cheek. Chondroid syringoma. *Arch Dermatol.* 2004 Jun;140(6):751-6. doi: 10.1001/archderm.140.6.751-b. PMID: 15210472.
 158. Park HJ, Shin KH, Yang WI, Suh JS. Growing mass on the medial aspect of the right proximal leg. *Clin Orthop Relat Res.* 2000 Nov;(380):279-83, 286-8. doi: 10.1097/00003086-200011000-00037. PMID: 11065002.
 159. De Fata Chillón FR, Nistal Martín M, Núñez Mora C, Alonso Dorrego JM, García Mediero JM, Rios González E, Martínez-Piñero Lorenzo L, De La Peña Barthel JJ. Siringoma condroide gigante de escroto. Primer caso descrito [Giant chondroid syringoma of the scrotum. First reported case]. *Arch Esp Urol.* 2001 Dec;54(10):1121-3. Spanish. PMID: 11852521.
 160. Nakayama H, Kishi A, Kajihara H. Hyaline cell-rich chondroid syringoma: epithelial nature of the hyaline cells. *Jpn J Clin Oncol.* 1996 Aug;26(4):237-42. doi: 10.1093/oxfordjournals.jjco.a023221. PMID: 8765182.
 161. Krishnamurthy A, Aggarwal N, Deen S, Majhi U, Ramshankar V. Malignant chondroid syringoma of the pinna. *Indian J Nucl Med.* 2015 Oct-Dec;30(4):334-7. doi: 10.4103/0972-3919.164057. PMID: 26430319; PMCID: PMC4579620
 162. Shashikala P, Chandrashekhar HR, Sharma S, Suresh KK. Malignant chondroid syringoma. *Indian J Dermatol Venereol Leprol.* 2004 May-Jun;70(3):175-6. PMID: 17642601.
 163. Gotoh S, Ntege EH, Nakasone T, Matayoshi A, Miyamoto S, Shimizu Y, Nakamura H. Mixed tumour of the skin of the lower lip: A case report and review of the literature. *Mol Clin Oncol.* 2022 Mar;16(3):69. doi: 10.3892/mco.2022.2502. Epub 2022 Jan 24. PMID: 35251620; PMCID: PMC8848767.
 164. Nel CE, van der Byl D, Grayson W. Malignant Chondroid Syringoma: A Report of Two Cases with a Sarcomatous Mesenchymal Component. *Dermatopathology (Basel).* 2019 Jun 26;6(2):77-84. doi: 10.1159/000495610. PMID: 31700847; PMCID: PMC6827459.
 165. Paraskevopoulos K, Cheva A, Koloutsos G, Matzarakis I, Vahtsevanos K. Chondroid syringoma of the medial canthus. *Case Rep Otolaryngol.* 2014;2014:158527. doi: 10.1155/2014/158527. Epub 2014 Mar 11. PMID: 24744935; PMCID: PMC3972857.
 166. KLEIN I. Ein sogenannter Speicheldrüsenmischttumor an der Haut der Vulva [A so-called salivary mixed tumor on the skin of the vulva]. *Geburtshilfe Frauenheilkd.* 1956 Aug;16(8):721-4. German. PMID: 13365893.
 167. Manni HJ, van Raalte JA. A mixed tumor of the skin of the nose. *ORL J Otorhinolaryngol Relat Spec.* 1983;45(2):96-101. doi: 10.1159/000275630. PMID: 6302620.
 168. Nakamura S, Nakayama K, Ito F, Furuya K. Multiple mixed tumor (pleomorphic adenoma): a clinicopathological study. *J Dermatol.* 1988 Jun;15(3):268-72. doi: 10.1111/j.1346-8138.1988.tb03689.x. PMID: 2846667.
 169. Su A, Apple SK, Moatamed NA. Pleomorphic adenoma of the vulva, clinical reminder of a rare occurrence. *Rare Tumors.* 2012 Jan 2;4(1):e16. doi: 10.4081/rt.2012.e16. Epub 2012 Mar 8. PMID: 22532914; PMCID: PMC3325743.
 170. Mark I, Rothberg M. Mixed tumor of skin of external auditory canal. *AMA Arch Otolaryngol.* 1951 May;53(5):556-9. doi: 10.1001/archotol.1951.03750050076008. PMID: 14829127.
 171. Terrill RQ, Groves RJ, Cohen MB. Two cases of chondroid syringoma of the hand. *J Hand Surg Am.* 1987 Nov;12(6):1094-7. doi: 10.1016/s0363-5023(87)80122-3. PMID: 2826570.
 172. Silva LG, Brandão FN, Paredes F. "Tumor mixto" plantar simulando clinicamente un poroma écrino [Mixed plantar tumor clinically simulating eccrine poroma]. *Med Cutan Ibero Lat Am.* 1976;4(4):253-9. Portuguese. PMID: 190487.
 173. Hilton JM, Blackwell JB. Metastasising chondroid syringoma. *J Pathol.* 1973 Feb;109(2):167-70. doi: 10.1002/path.1711090210. PMID: 4352760.
 174. Bates AW, Baithun SI. Atypical mixed tumor of the skin: histologic, immunohistochemical, and ultrastructural features in three cases and a review of the criteria for malignancy. *Am J Dermatopathol.* 1998 Feb;20(1):35-40. doi: 10.1097/00000372-199802000-00007. PMID: 9504667.

Added from review references

175. S. T. González, T. G. Oliveros, G. N. Franco, and A. R. Garibay, "Siringoma condroide. Presentación de dos casos," *Arch Surg*, vol. 16, no. 1, p. 30, Jan. 2007.
176. Ferragina F, Barca I, Sorrentino A., Kallaverja E., Cristofaro M.G., Cutaneous chondroid syringoma: A case series, *Oral and Maxillofacial Surgery Cases*, Volume 9, Issue 1, 2023, 100291, ISSN 2214-5419, <https://doi.org/10.1016/j.omsc.2022.100291>.

177. Favareto SL, Pellizzon ACA, Lopes Pinto CA, Bertolli E, Castro DG. The Role of Radiation Therapy as an Adjuvant Treatment in Nodal Metastasis of Malignant Chondroid Syringoma. *Cureus*. 2020 Nov 6;12(11):e11360. doi: 10.7759/cureus.11360. PMID: 33304693; PMCID: PMC7720919.
178. Fernandez-Flores A, Cassarino DS. Malignant cutaneous mixed tumor with sebaceous differentiation. *Rom J Morphol Embryol*. 2017;58(3):977-982. PMID: 29250677.
179. Ishimura E, Iwamoto H, Kobashi Y, Yamabe H, Ichijima K. Malignant chondroid syringoma. Report of a case with widespread metastasis and review of pertinent literature. *Cancer*. 1983 Nov 15;52(10):1966-73. doi: 10.1002/1097-0142(19831115)52:10<1966::aid-cnrcr2820521032>3.0.co;2-7. PMID: 6194872.
180. Ka S, Gnanon F, Diouf D, Dieng MM, Thiam J, Gaye M, Dem A. Malignant chondroid syringoma in a West African cancer institute: A case report. *Int J Surg Case Rep*. 2016;25:137-8. doi: 10.1016/j.ijscr.2016.06.029. Epub 2016 Jun 23. PMID: 27372026; PMCID: PMC4929341.
181. Malik R, Saxena A, Kamath N. A rare case of malignant chondroid syringoma of scalp. *Indian Dermatol Online J*. 2013 Jul;4(3):236-8. doi: 10.4103/2229-5178.115533. PMID: 23984246; PMCID: PMC3752488.
182. Matz LR, McCully DJ, Stokes BA. Metastasizing chondroid syringoma: case report. *Pathology*. 1969 Jan;1(1):77-81. doi: 10.3109/00313026909061040. PMID: 4330556.
183. Redono C, Rocamora A, Villoria F, Garcia M. Malignant mixed tumor of the skin: malignant chondroid syringoma. *Cancer*. 1982 Apr 15;49(8):1690-6. doi: 10.1002/1097-0142(19820415)49:8<1690::aid-cnrcr2820490825>3.0.co;2-o. PMID: 6279274.
184. ROSBOROUGH D. MALIGNANT MIXED TUMOURS OF SKIN. *Br J Surg*. 1963 Jul;50:697-9. doi: 10.1002/bjs.18005022505. PMID: 14043691.
185. Sánchez Herreros C, Belmar Flores P, De Eusebio Murillo E, Díez Recio E, Cuevas J. A case of cutaneous malignant mixed tumor treated with mohs micrographic surgery. *Dermatol Surg*. 2011 Feb;37(2):267-70. doi: 10.1111/j.1524-4725.2010.01865.x. Epub 2011 Jan 31. PMID: 21281386.
186. Sánchez Yus E, Aguilar A, Urbina F, Cristóbal MC, Vázquez F, Requena L. Malignant cutaneous mixed tumor. A new case with unusual clinical features. *Am J Dermatopathol*. 1988 Aug;10(4):330-4. doi: 10.1097/00000372-198808000-00008. PMID: 2843063.
187. Tural D, Selçukbiricik F, Günver F, Karışmaz A, Serdengeçti S. Facial localization of malignant chondroid syringoma: a rare case report. *Case Rep Oncol Med*. 2013;2013:907980. doi: 10.1155/2013/907980. Epub 2013 Feb 13. PMID: 23476847; PMCID: PMC3586475.
188. Watson JA, Walker MM, Smith NP, Hunt DM. Malignant chondroid syringoma--a rare cause of secondary bone tumour. *Clin Exp Dermatol*. 1991 Jul;16(4):306-7. doi: 10.1111/j.1365-2230.1991.tb00384.x. PMID: 1665401.
189. Webb JN, Stott WG. Malignant chondroid syringoma of the thigh. Report of a case with electron microscopy of the tumour. *J Pathol*. 1975 May;116(1):43-6. doi: 10.1002/path.1711160107. PMID: 169339.
190. Stromberg B, Thorne S, Dimino-Emme L, Geiss R. Atypical chondroid syringoma. *Nebr Med J*. 1991 May;76(5):141-7. PMID: 1652102.
191. Mittal HK, Bist SS, Harsh M. Atypical Facial Chondroid Syringoma, A Rare Clinical Entity: Case Report with Review of Literature. *Indian J Otolaryngol Head Neck Surg*. 2020 Jun;72(2):274-277. doi: 10.1007/s12070-019-01779-8. Epub 2020 Jan 3. PMID: 32551288; PMCID: PMC7276458.
192. Halpert B. Salivary Gland Tumors in Rare Sites Report of Two Cases. *Yale J Biol Med*. 1933 May;5(5):469-71. PMID: 21433574; PMCID: PMC2606480.
193. RABINOVITCH J, GRAYZEL D, ACHS S. Mixed tumor of the bridge of the nose. *Arch Surg (1920)*. 1948 Jul;57(1):148-53. doi: 10.1001/archsurg.1948.01240020151012. PMID: 18123781.
194. Kim SJ, Ahn SK, Choi EH, Lee SH. Unusual cases of syringoma of the forehead. *J Dermatol*. 1996 Jan;23(1):61-3. doi: 10.1111/j.1346-8138.1996.tb03971.x. PMID: 8720262.
195. Kitazawa T, Hataya Y, Matsuo K. Chondroid syringoma of the orbit. *Ann Plast Surg*. 1999 Jan;42(1):100-2. doi: 10.1097/00000637-199901000-00018. PMID: 9972727.
196. Baran JL, Hoang MP. Apocrine mixed tumor of the skin with a prominent pilomatricomal component. *J Cutan Pathol*. 2009 Aug;36(8):882-6. doi: 10.1111/j.1600-0560.2008.01137.x. PMID: 19586498.
197. Siraj F, Jain D. Cutaneous mixed tumor with prominent pilomatricomal differentiation. *J Cutan Pathol*. 2012 Jul;39(7):718-20. doi: 10.1111/j.1600-0560.2012.01870.x. Epub 2012 May 11. PMID: 22574897.
198. Kazakov DV, Kacerovska D, Skalova A, Zelger B, Schaller J, Shelekhova K, Michal M. Cutaneous apocrine mixed tumor with intravascular tumor deposits: a diagnostic pitfall. *Am J Dermatopathol*. 2011 Dec;33(8):775-9. doi: 10.1097/DAD.0b013e31820b7b9c. PMID: 21785330.
199. Azari-Yam A, Abrishami M. Apocrine mixed tumor of the eyelid: a case report. *Diagn Pathol*. 2016 Mar 24;11:32. doi: 10.1186/s13000-016-0483-5. PMID: 27013174; PMCID: PMC4806417.
200. Palit A, Sethy M, Nayak AK, Ayyanar P, Behera B. Dermoscopic features in a case of chondroid syringoma. *Indian J Dermatol Venereol Leprol*. 2021 Jan-Feb;87(1):89-92. doi: 10.4103/ijdv.IJDVL_167_20. PMID: 32969355.
201. Bal A, Dazé R, Brahs A, Miller R. Chondroid syringoma with osteoma cutis. *JAAD Case Rep*. 2022 Jan 31;22:2-4. doi: 10.1016/j.jdc.2022.01.023. PMID: 35242977; PMCID: PMC8886313.